

# FIGHTING FRACTURES

Although pets with fractured teeth won't show their pain, it's important to treat the problem before infection spreads.

By Brett Beckman, DVM, Diplomate American Veterinary Dental College



## Key Points

**FRACTURED TEETH** can become infected and die.

**DEAD AND DISCOLORED TEETH** need root-canal therapy or extraction to prevent further problems.

**ANIMALS WITH FRACTURED TEETH** almost never show signs of discomfort.

**DOGS OFTEN FRACTURE THEIR TEETH** on hard chew objects.

**TEETH THAT ARE FRACTURED BUT STILL ALIVE** may be restored.

Seymour, a five-year-old mixed breed dog, loves to chew everything from sticks and branches to rawhide. He especially likes ice.

At a recent examination, Seymour's veterinarian noticed that a portion of the enamel on one of the dog's upper teeth was fractured (Photo 1, white arrow). A portion of the cracked enamel was still present and attached to the gum (Photo 1, black arrow).

Seymour's pet parents had not noticed anything unusual about Seymour. That's typical. Most pets with tooth fractures don't show signs of pain. Unfortunately, they may silently suffer for months to years before the problem becomes so bad that their appetite decreases, they drop food while eating, appear less active or sleep more during the day. Seymour showed none of these symptoms, but fortunately his veterinarian noticed the problem and referred his case to our veterinary dental specialty office for treatment.

## Treatment Options

How we treat tooth fractures depends on the extent of the fracture, whether any of the pulp (the soft, living center of the tooth) is exposed, what an x-ray shows and the status of the areas around the tooth.

The longer a tooth fracture is left untreated, the worse it gets. For example, take a look at an x-ray of Seymour's tooth in Photo 2. The arrow shows a dark area around the root tip where the bone has been destroyed. This process starts when

## Chew on This

Help prevent tooth fractures by giving your dogs products approved by the Veterinary Oral Health Council. [www.vohc.org](http://www.vohc.org).

bacteria get into the tooth pulp. The bacteria infect the pulp, which then dies. Then the infection starts to leak out of the tooth's root tip and destroy the bone. In severe cases, the infection breaks through the bone and spreads into the skin, forming a fistula on the dog's face (Photo 3).

If the patient is young and the pulp is exposed for less than 48 hours, a veterinary dentist may be able to save the tooth without extracting it or doing root-canal therapy. If you think your pet may have fractured a tooth, see your veterinarian right away.

Not all teeth that have fractures need extraction or root-canal therapy. If only the enamel is fractured, it's possible that all that's needed is to smooth the enamel to eliminate sharp edges and prevent any further fracture. Many times, sealing the dentin (the tooth layer below the enamel) with bonding and composite can save the tooth by preventing any further chance for bacteria to enter the tooth. Patients with a tooth that has been

protected this way must have that tooth x-rayed again in six to twelve months to ensure that the tooth remains alive.

If a dental x-ray shows that the tooth is dead or if pulp is visible, treatment options include root-canal therapy or extraction of the tooth. Another sign that a tooth may need root-canal therapy or extraction is if part or all of it turns pink, grey, purple or black (Photo 4).

In most cases, the tooth can be saved with root-canal therapy, in which the nerve and pulp are removed and the inside of the tooth is cleaned and sealed. Crowns are a good option for large teeth that may undergo additional damage.

In Seymour's case, bacteria had killed the pulp. His pet parents decided on tooth extraction. Although Seymour showed no obvious signs that he was in pain prior to the procedure, his owners noticed within a few days of the extraction that he was much more playful than he had been for a long time.

## Preventing Fractures

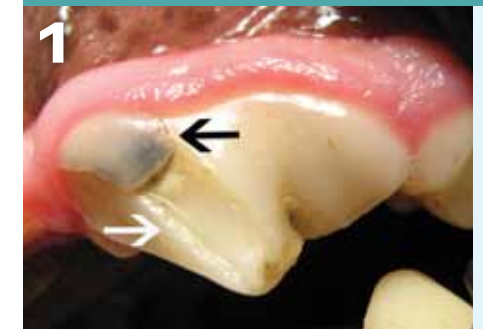Prevention is the key to avoiding tooth fractures. Hard objects of any type often fracture teeth. If an object or chew is not easily bendable, it can fracture a pet's tooth. Roughhousing with other dogs can result in tooth fractures, too.

Common objects that can damage teeth include:

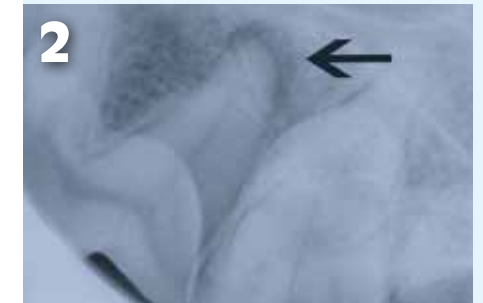
- rawhide
- cow hooves
- bones
- large sticks or branches
- rocks
- ice
- non-bendable chews

Remember that fractured teeth require prompt care. Even if your pet doesn't show any signs of pain, be sure to schedule regular oral examinations for your pets. ■

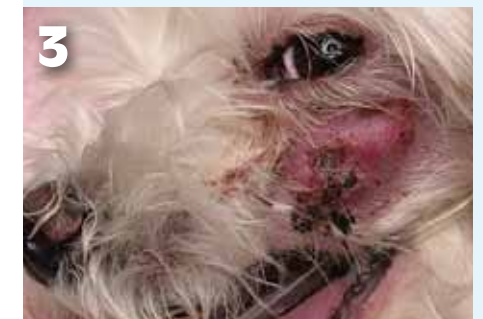*Dr. Brett Beckman specializes in veterinary dentistry.*



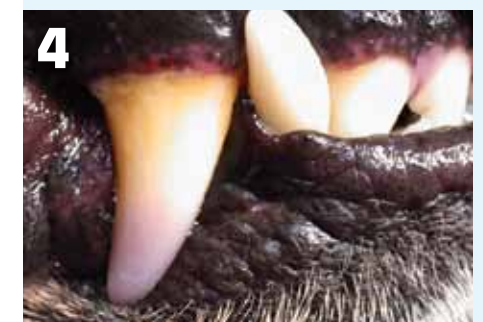This fracture on Seymour's tooth (white arrow) exposed dentin, the tooth layer just below the protective enamel. A portion of the fractured enamel is still attached at the gum line (black arrow).



The arrow points to a dark area where infection has destroyed the bone around Seymour's fractured tooth.



This patient developed a facial fistula (an opening where infection drains) after fracturing the same tooth as Seymour.



This tooth has purple discoloration at the tip, indicating that the tooth is dead.