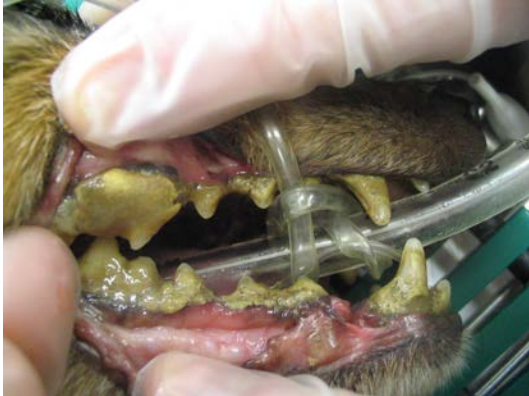
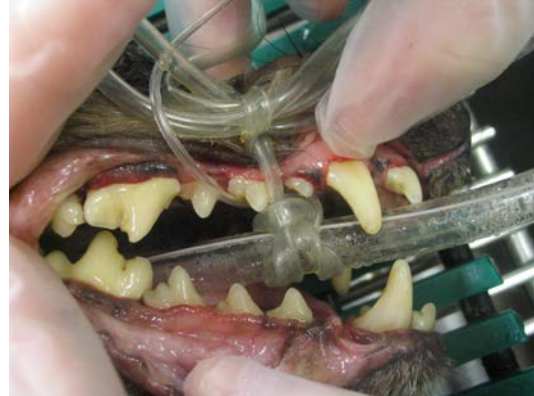
Dentistry at Frey Pet Hospital

Did you know that 80% of animals over 5 years of age have some form of dental disease? Studies have shown that regular dental cleanings extend pet's lives an average of 2-4 years! Tartar and bacteria in the mouth causes inflammation and damages the attachment of the gums to the teeth. Over time the inflamed gum tissue and infection creates significant pain for your pet. Additionally, this infection can be transported throughout the body most commonly the heart, liver, lungs, kidneys, and spine. At Frey Pet Hospital, we utilize the latest techniques and modern equipment to provide the best dental care for your pet. The following explains exactly what is involved in the dentistry procedure at Frey Pet Hospital.



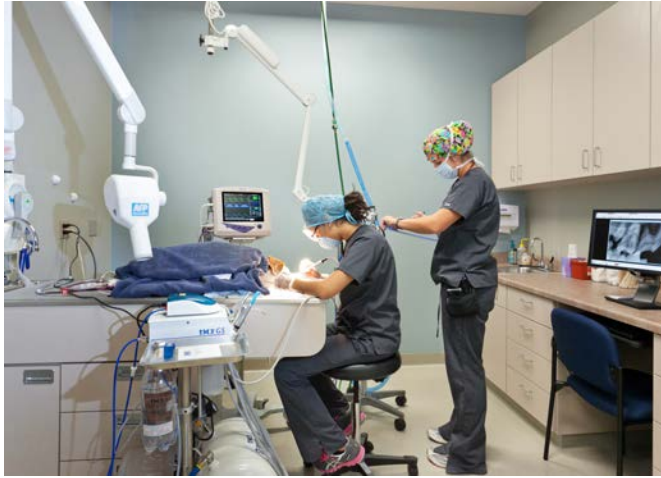Teeth Before Cleaning



Teeth After Cleaning

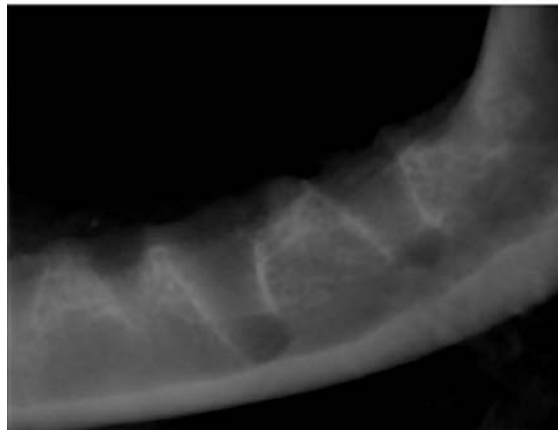
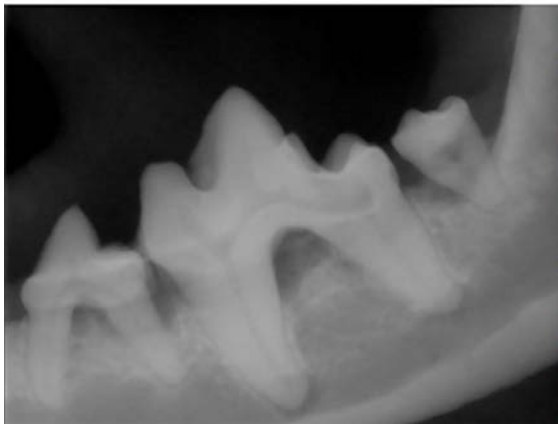Ten steps to a healthy mouth

1. **Physical examination.** All of our patients receive an examination of the mouth as part of their general physical exam. During this oral exam, we can evaluate for obvious disease in the mouth. We will grade the severity of the visible dental disease from 1 to 4, with one being minor dental problems and four being major dental problems. This gives us a rough idea of what we may need to do during a dental procedure. It is difficult to fully examine the mouth of an awake pet and we can only see the crowns of the teeth, NOT the roots. We will provide a treatment plan for the procedures we may need to do. We may find more problems during the dental procedure, and in this case we will call you to discuss our findings and give you an approximate cost for the procedure.
2. **Preoperative bloodwork and examination.** Any pet that receives general anesthesia at Frey Pet Hospital gets a full physical examination on the day of surgery, and blood tests are performed to make sure your pet is in good health prior to general anesthesia.
3. **General anesthesia.** Dentistry in dogs and cats requires a general anesthetic, and cannot be properly done without anesthesia. The anesthetic protocol is tailored to your pet's age, breed, and health status. Your pet will also have an IV catheter in place to allow quick access to the blood stream for fluids and/or medications. The procedure is done under a light plane of inhalant anesthetic (just like in human hospitals), and a sophisticated monitor will assist our Board Certified Anesthetist or Registered Veterinary Technician in monitoring your pet's vital signs. This monitor measures his/her blood pressure, body temperature, heart rate, and oxygen levels in the blood, respirations, and a continuous ECG to monitor the heart.



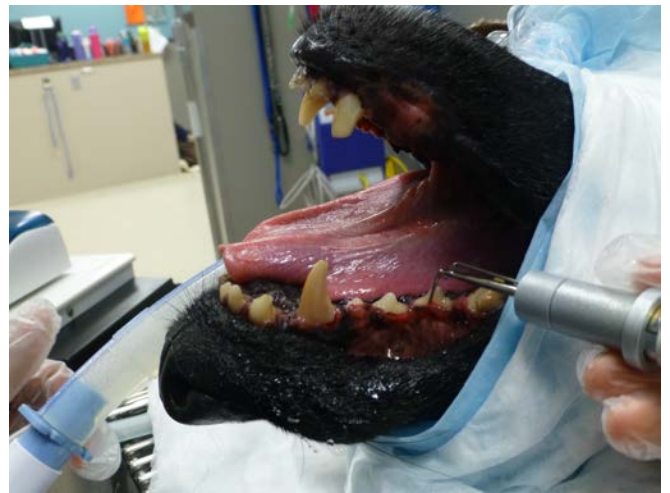Pet having teeth cleaned and anesthetic monitoring in our dental suite.

4. **Intraoral Radiology.** We use state-of-the-art digital radiology to analyze the teeth of all patients undergoing a dental procedure. The only way to accurately evaluate the whole tooth is to x-ray. The crown is the only portion of the tooth visible in the mouth; the root of the tooth is embedded in a socket in the jaw bone. In many cases the crown of the tooth may appear normal, but an x-ray of the tooth may reveal a problem with the root that requires treatment. Once all of the teeth in the mouth have been x-rayed, the treating veterinarian reviews the x-rays and determines which therapy is required for each tooth.



Once we have removed the affected teeth we may take another x-ray to make sure that all of the roots have been removed and there is no damage to the jawbone.

5. **Scaling.** Scaling is the process where the tartar is removed from the teeth. Tartar is produced by bacteria that lives on the teeth. Tartar causes inflammation of the gums (gingivitis) and this leads to recession of the gums, exposure of the tooth roots, and eventually loss of the tooth. We remove the tartar

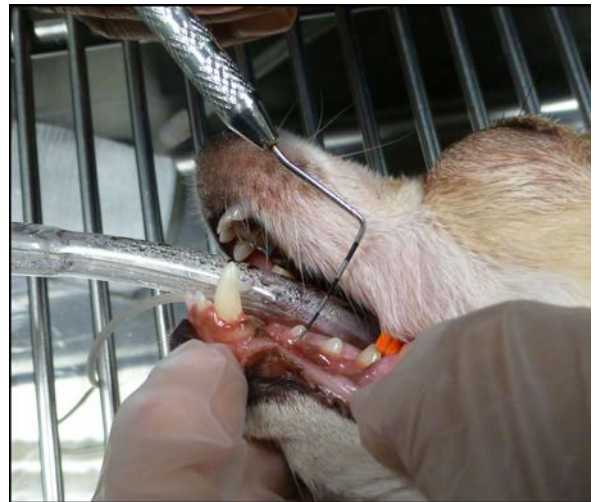

with a combination of an ultrasonic scaler and hand scaling (similar equipment as the human dental hygienists). Removal of the tartar on the teeth is vital to improving the health of the mouth and it also removes one of the sources of the patient's halitosis (bad breath).

The ultrasonic scaler is being used to remove tartar

6. **Polishing.** Just like when you go to the dentist, a similar teeth cleaning procedure is performed. The mechanical removal of the plaque and calculus causes microscopic roughening of the tooth surface. This roughening increases the retentive ability of the tooth for plaque and calculus, which will build up faster and increase the rapidity of periodontal disease progression. Polishing will smooth the surface and decrease the adhesive ability of plaque.

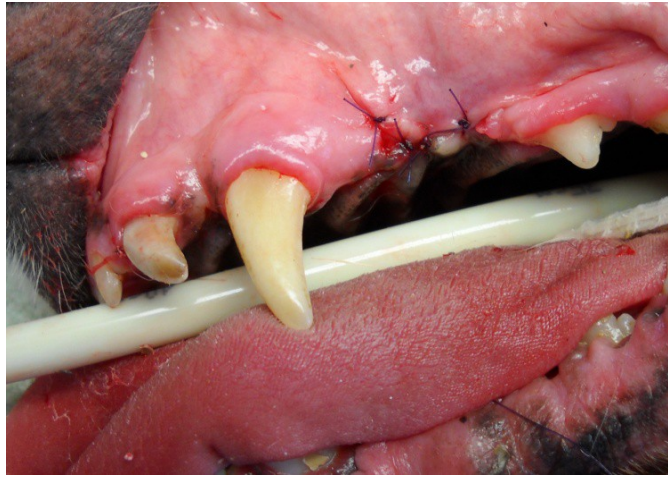
7. **Periodontal probing.** Once the teeth have been scaled, the veterinarian examines each tooth individually with a periodontal probe. We use the probe to look for pockets. Pockets are caused by the gum losing its attachment to the tooth. Bacteria and tartar can accumulate in the pocket causing the wall of the tooth socket to erode, which leads to loosening of the tooth in the socket and eventually can cause tooth loss. A small pocket may be cleaned and flushed, but a deep pocket usually requires that the affected tooth be removed.



A

periodontal probe being used to detect periodontal pockets.

8. **Charting.** The combination of radiology and periodontal probing allows us to accurately diagnose any problems with the teeth and formulate a treatment plan. We use a special chart to record our findings and treatments.
9. **Extractions and Oral Surgery.** We are very conservative and leave teeth in whenever possible. However, your pet's health and comfort is our top priority. If we decide that a tooth cannot be saved, it will be extracted. The first step is to place a local anesthetic to numb the area. Even though the patient is under an anesthetic, removing a tooth can cause pain. The local block gives the patient immediate pain relief and the effect lasts for several hours to also offer the patient post-operative comfort. Once the block has taken effect, we elevate a flap of gum tissue to expose the jaw bone. A high speed drill is used to cut the tooth into sections to allow for easier removal. The tooth is removed using instruments called elevators. Once the tooth is removed the socket is cleaned. A post extraction x-ray may be necessary to make sure that all of the roots have been removed. Once we have confirmed that there are no tooth root remnants, we close the socket using the gum flap. This prevents food material from becoming lodged in the empty socket. The flap is sutured with a fine absorbable suture.



The tooth has been removed and a gingival flap is sutured over the socket.

10. **Post- operative care.** We will give specific post-operative instructions. This may include soft food and no teeth brushing for a few days. We will discuss treatment options designed to reduce the accumulation of tartar on the teeth. The treatment options may include a combination of toothbrushing, applying sealants, special dental diets (Hills t/d), or chews (CET chews), and oral rinses.